

MUSCLES OF THE UPPER LIMB

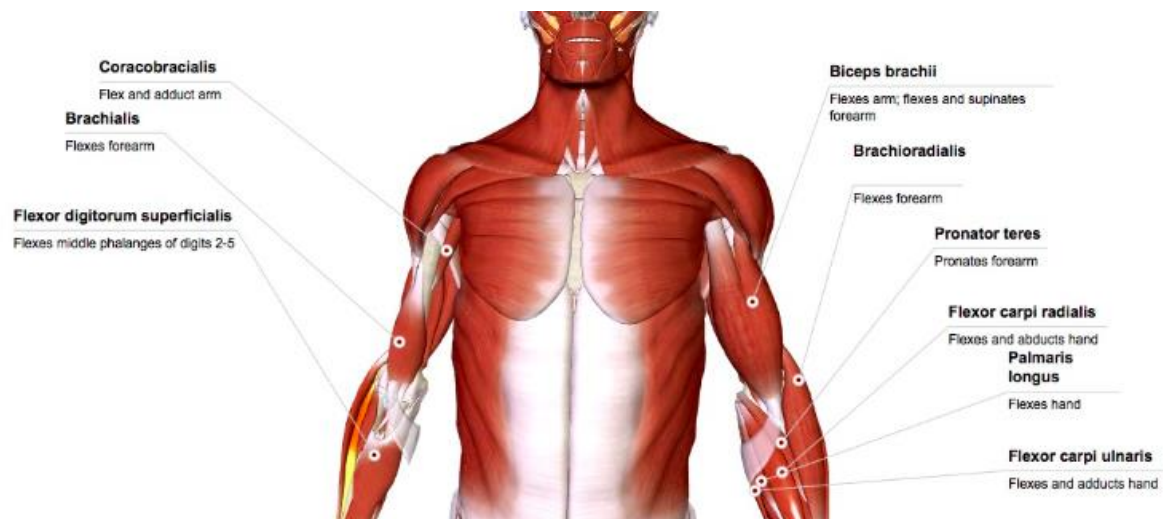
Anterior	Coracobrachialis	Biceps brachii	Brachialis
Action	Flexes and adducts arm	Flexes arm; flexes and supinates forearm	Flex forearm
Origin	Coracoid process of scapula	Supraglenoid tubercle of scapula, coracoid process of scapula	Distal half of humeral shaft
Insertion	Shaft of humerus	Bicipital tuberosity of radius	Ulna tuberosity

Posterior	Triceps brachii	Anconeus
Action	Extend forearm (long head also adducts arm)	Extends forearm
Origin	Infraglenoid tubercle of scapula (LH), shaft of humerus (lat&med. Heads)	Lateral epicondyle of humerus
Insertion	Olecranon process of ulna	Olecranon process of ulna

Forearm Anterior flexor/pronator group

Superficial	Brachioradialis	Pronator teres	Flexor carpi radialis	Palmaris longus	Flexor carpi ulnaris
Action	Flexes forearm	Pronate forearm	Flexes and abducts hand	Flexes hand	Flexes and adducts hand
Origin	Lateral supracondylar line of humerus	Medial epicondyle of humerus (& supracondylar line)	Medial epicondyle of humerus	Medial e. of humerus	Medial e. of humerus
Insertion	Styloid process of radius	Lateral surface of radius	Metacarpals 2&3	Flexor retinaculum	Pisiform, hamate & metacarpal 5

Intermediate	Flexor digitorum superficialis
Action	Flexes middle phalanges of digits 2-5
Origin	Medial e. of humerus & coronoid process of ulna
Insertion	Middle phalanges of digits 2-5



Deep	Flexor digitorum profundus	Flexor pollicis longus	Pronator quadratus
Action	Flexes digits 2-5	Flexes digit 1	Pronates forearm
Origin	Ulna and interosseous membrane	Radius and interosseous membrane	Anterior border of ulna
Insertion	Distal phalanges of digits 2-5	Distal phalanx of digit 1	Anterior border of radius