Lecture 1 Thoracic Spine

Functional Overview
- Protects organs e.g. Heart and lungs
- Limited motion: relatively rigid structure
- Soft tissue injuries related to:
  - Sports e.g. Golf, tennis, rowing and cricket
  - Lifting or reaching activities
  - Prolonged postural strain

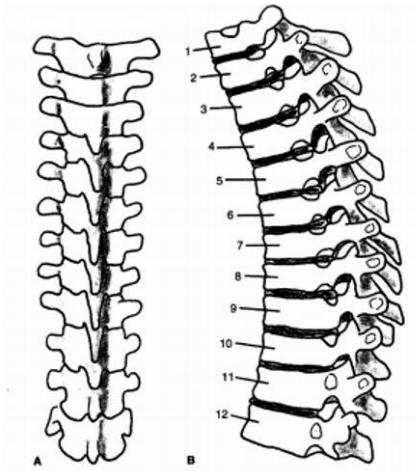

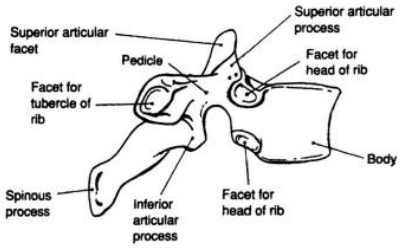

Anatomy

- Upper = T1-T4
- Middle = T5-T8
- Lower = T9-T12

Key movement = rotation
- One vertebra has up to 12 articulations
- Oblique Z joints
- Each thoracic segment articulates with a pair of ribs
- Ribs articulate with the spinal column posteriorly and sternum anteriorly
  - Ribs 1-7 = 'true' ribs - costochondral joint
  - Ribs 8-10 = 'false' ribs
  - Ribs 11-12 = 'floating' ribs

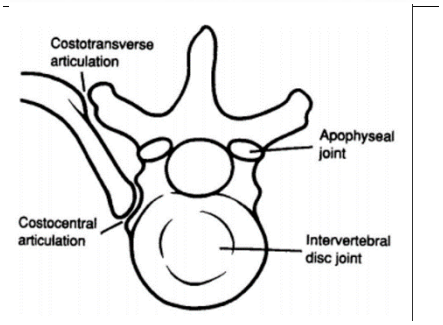

Biomechanics: Vertebrae
- Ribs and thin discs restrict available motion
- **Rotation** favoured by Z joint orientation (superior facet faces post, sup and lat)
- Sagittal motion greatest in lower TS and LS

Positions and Patterns
- Loose packed: neutral to slight flexion
- Close packed: extension

Thoracic Spine Pain

Thoracic outlet = space between the clavicle and first rib (compression of blood vessels and
nerves)

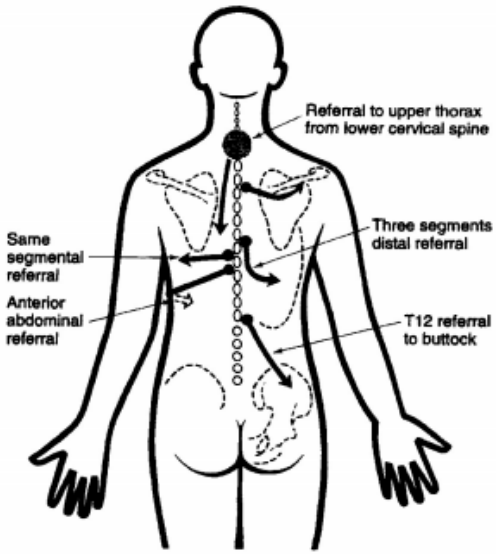

Referred Pain
- TS can produce localised pain but can also refer pain
- TS is a common site and source of referral
  - Cervical and lumbar spine can refer to TS
  - Rule out red flags
  - Symptoms can mimic visceral and cardiorespiratory problems
- Dysfunction in TS can cause neck and shoulder pain
- May influence breathing (inspiration more common)
- Clowards pain: lower part of the neck can refer pain to between the shoulder blades

Red flags: inflammations, infections, osteoporotic fractures and tumours

Excessive kyphosis

- Resulting in: protracted shoulders and forward positioning of head
- Cause: osteoporosis, degenerative nature

Extrinsic Disorders

- Referred pain from lower CS or LS
- Inflammatory
  - Ankylosing spondylitis (young males: SIJ and rib articulations in thoracic spine)
- Visceral pain
  - Peptic ulcer, cardiac disease, oesophageal reflux, pulmonary embolism
- Tumours
  - Multiple myeloma: originates in bone marrow in thoracic area
- Infection
  - TB
- Metabolic
  - Osteoporosis/osteoporotic fractures
    - Post menopausal women, age
    - Usually from trauma/trigger
  - Paget's Disease
- Herpes Zoster (shingles)
  - Rash follows dermatomes

Relationship between thoracic spine and heart disease

Feature	Referred pain from thoracic spine	Myocardial ischemia
Age	Any age, especially 20–40 years	Older, with increased possibility with increased age
History of injury	Sometimes	No
Site and radiation	Spinal and paraspinal, arms, lateral chest, anterior chest, substernal, iliac crest	Retrosternal, parasternal, jaw, neck, inner arms, epigastrium, interscapular
Type of pain	Dull, aching, occasionally sharp, severity related to activity, site and posture, sudden onset and offset	Constricting, vice-like ('clenched-fist' sign) may be burning, gradual onset and offset
Aggravation	Deep inspiration, postural movement of thorax, certain activities (e.g. slumping or bending, walking upstairs, lifting, sleeping or sitting for long periods)	Exercise, activity, heavy meals, cold, stress, emotion
Relief	Maintaining erect spine, lying down, firm pressure on back (e.g. leaning against wall)	Rest Glyceryl trinitrate
Associations	Chronic poor posture, employment requiring constant posture such as at a keyboard or computer	Cardiac risk factors such as family history, obesity, smoking, dyspnea, nausea, tiredness, pallor, sweating, vomiting

Comparison of clinical features of chest pain of cardiac origin and that from thoracic spine

Differentiation of visceral disorders

- Assess for mechanical pattern
  - Trauma/injury
  - Posture
  - Movement
  - Reproduce S&S with palpation with PAIVMs
    - If reproduced, it's not normally visceral disease but rather MSK
    - Be suspicious of something else if you cannot reproduce the pain
- Visceral pain rarely eased by lying down

Intrinsic Disorders

We are the first line of screening when it comes to physiotherapy in the private sector (i.e. 75% non-referred)

- Trauma
  - Fracture: touch vertebra and it's markedly tender
  - Ligament sprain
  - Mm strain
- Spinal nerve/nerve root compromise
  - Uncommon: thin discs (herniations are rare), decreased movement in the area
  - Pain and P&N follows the dermatome
  - Disc lesions more common in lower T vertebrae
- Degenerative joint disease
- Hypomobility/hypermobility disorders
- T4 syndrome
- Scheuermann's disease
- Idiopathic adolescent scoliosis
- Chest deformities

Spinal Nerve Compromise

- Uncommon
  - Usually bad habits include flexing which opens space up
- Irritation more frequent
- 0.1-0.6% disc lesions, usually T11 and T12
- Dermatomal sensation changes
- Radicular pain
- Cord compression possible from prolapsed disc --> surgery

Degenerative Joint and Disc Disease

- X-ray
  - Decreased disc space
  - Osteophytes (come off anterior vertebrae), bony fusion
- Can lead to reduced mobility i.e. hypomobility disorder (soft tissue, localised), but DJD is more structural
- Poor correlation between x-ray changes and pain
- Decreased AROM, PPIVMs down many levels
- PAIVMs stiff, painful
- Treatment: can't treat
  - Manual Rx: PAIVMs, PP joint movements, STM, massage
  - Postural education
  - Exercises: stretch and strengthen, general vs specific exercises
  - Aim: restore movement on a multilevel

Hypomobility Disorders

- Local/generalised pain due to reduced mobility
  - Following injury
  - Postural
- Decreased AROM, PPIVMs
- Local PAIVMs stiff, painful over hypomobile segments
- Treatment: can treat
  - PAIVMs, PP joint movements
  - Manipulation
    - Includes: high velocity thrust techniques - good results for patient
  - Traction, massage
  - Exercise
    - Mobilising exercises: arms and butt against wall - bring arms up and down - maintain contact and neutral lumbar spine

Stretches for stiff thoracic spine into extension

- Bakballs
- Foam roller
- Swiss ball
- Sitting in chair: rotating
- Yoga position: spinal twist
- Extension thrusts on the edge of a wedge where the transverse spinous process sits in a dip

Hypermobility

- May be localised or generalised TS pain
- Causes
  - Underlying hypermobility (genetic)
  - Poor motor control (static and/or dynamic)
  - Combination of above
- O/E:
  - Excessive range into one or more TS movements
  - Poor static and/or dynamic postural control
- Treatment:
  - Exercise: general (walking, swimming) // specific (postural, strengthening)
  - Education

T4 Syndrome

- Controversial - does it actually exist?
- Mechanical irritation of sympathetic chains (hypothetical)
  - Sympathetic ganglion sit very close to the thoracic spine
- Pain 'between shoulder blades'
- Diffuse upper arm pain, P&N, numbness; diffuse post head, neck pain (non-dermatomal, autonomic)
- Cross out red flags i.e. Cord compression (bilateral symptoms etc.)
- Hypomobility T3-T4-T5 region
- Treatment:
  - Responds well to manual therapy
  - PAIVMs
  - Manipulation
  - Exercise

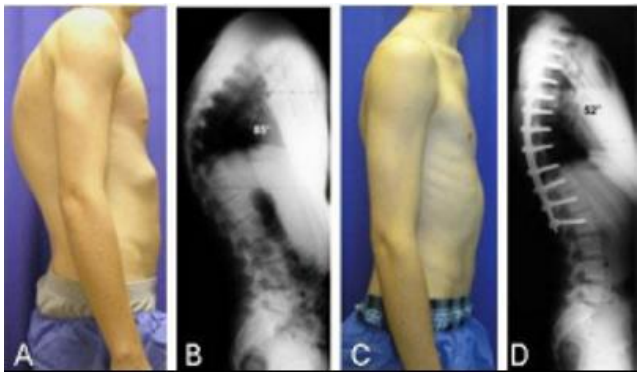

Scheuermann's Disease

- Disorder of the growth plates (osteochondritis)
- Adolescent M > F: during growth spurts
- Acute pain or asymptomatic
- Increasing kyphosis, limited extension
- X-ray
  - Irregularity of growth plates T9-L1
  - Wedging of vertebrae
  - Schmorl's nodes: protrusions of nucleus pulposus through the end plates
    - Key diagnostic criteria
    - X-ray: rough/bumpy end plates (lines between vertebrae) and compressed into a wedge
- Treatment
  - Education

Postural correction

  - Stretches
  - Abdominal mm strengthening
  - Extension exercises
- Medical Treatment
  - Brace
  - Surgery if > 50-75 degrees kyphosis

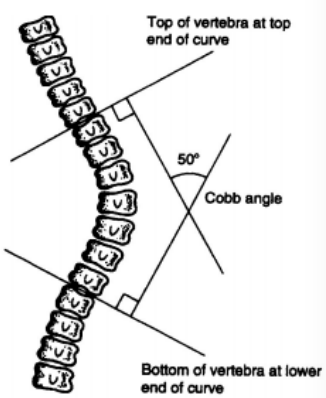

Idiopathic Adolescent Scoliosis

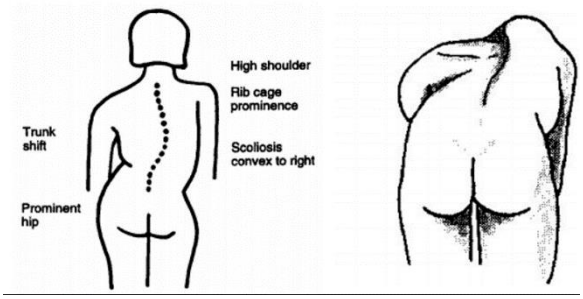

- 5% prevalence, usually mild
- 85% significant curves in girls
- Peripubertal period during growth spurt
- Screen 12-14 yo with a flexion test
    - Structural scoliosis: bony architecture
        - Bend forward, look along back and you can see a unilateral hump which will not disappear, unlike if it's postural scoliosis (see photo on right)
    - Postural scoliosis
        - Bend forward, the hump will go
- X-ray may be needed to monitor changes
- Cosmetic, resp and pain problems possible
- Treatment
    - Exercise for muscle imbalance (stretch tight mm, strengthen weak mm)
      Convex = stretched
      Concave = tight
- Medical Treatment:
    - Brace if growing: 30-45 degrees
    - Surgery if > 45 degrees

Scoliosis can be treated with a Harrington Rod

Chest deformities
- Pectus carinatum: pigeon
- Pectus excavatum: caved in
- Barrel chest

Chest and Rib Joint Pain
- Sternoclavicular joint
    - Sole articulation between arm and axial skeleton
- Manubriosternal joint
- Costovertebral joints
- Costochondral joints

Treatment
- Differential diagnostic challenge
- Consider cause of pain: overload vs. Stiffness vs. Injury: treat accordingly