

IMED4121 Muscles

SUPERFICIAL LAYER OF INTRINSIC BACK MUSCLES

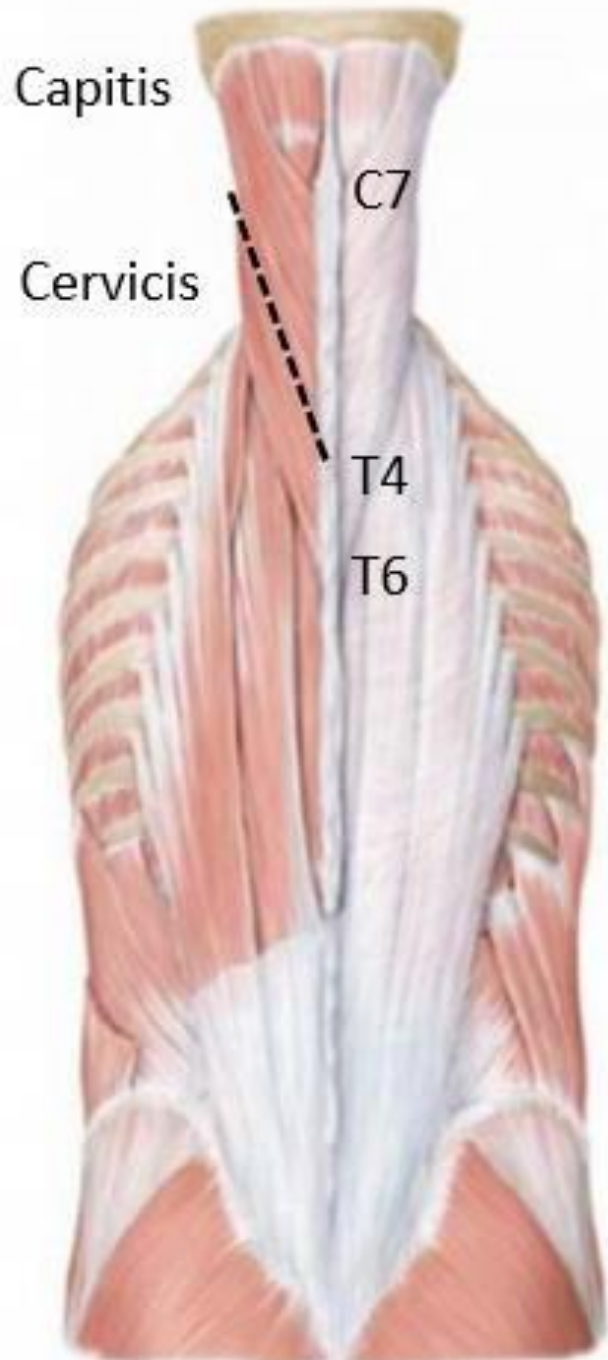
1. **Splenius capitis**

- nuchal ligament, spinous process (prox)
- mastoid process (dist)
- posterior rami of spinal nerves
- laterally flex & rotate neck ipsilaterally

2. **Splenius cervicis**

- nuchal ligament, spinous process
- tubercles of transverse process
- posterior rami of spinal nerves
- laterally flex & rotate neck ipsilaterally

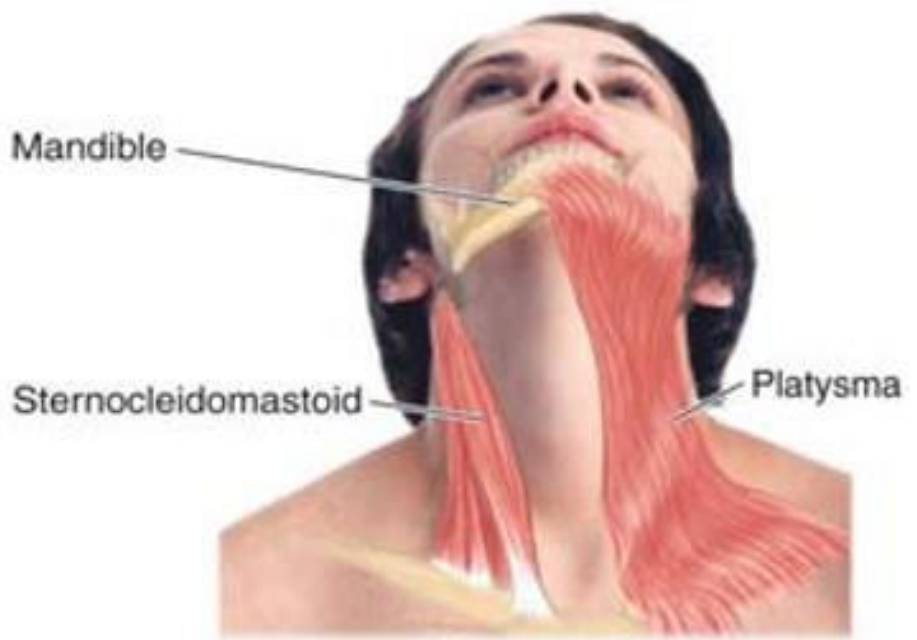
* together they extend the neck



SUPERFICIAL MUSCLES OF THE NECK

3. **Platysma**

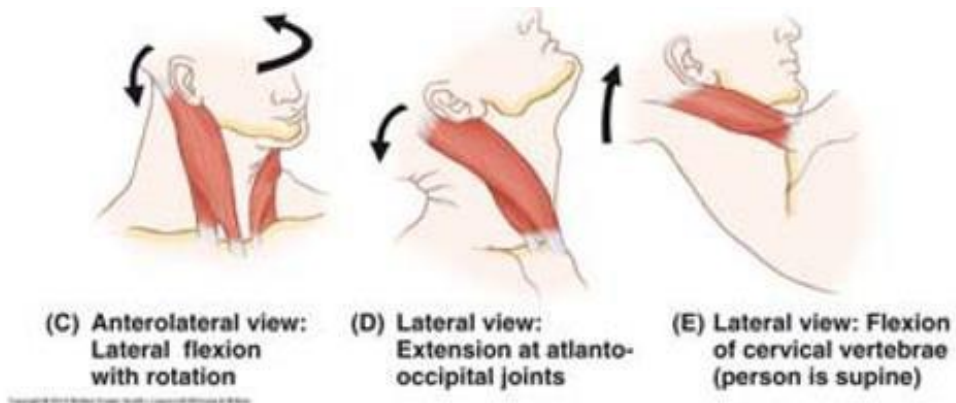
- inferior border of mandible (sup)
- fascia covering superior parts of pectoralis major and deltoid (inf)
- cervical branch of facial nerve
- widens mouth



(A) Anterior view

4. **Sternocleidomastoid – sternal / clavicular head**

- lateral surface of mastoid process & superior part of nuchal line
- anterior surface of manubrium (sternal head)
- superior surface of clavicle (clavicular head)
- spinal accessory nerve
- unilateral contraction: laterally flexes neck (ipsilaterally)
- bilateral contraction: extends neck at atlanto-occipital joint, flexes cervical vertebrae, thrusts chin forward
- elevates manubrium and medial ends of clavicle (assists pump-handle movement)



+ Assist pump-handle movements of deep inspiration