Compendium 1-The Organisation & Characteristics of Humans:

Anatomy: Investigating structure & relation of body parts.

- Gross: macroscopic eg) systemic, regional (arm-nerves/muscles).
- Surface: external body and its relation to deeper structures eg) ribs a landmark of where heart lies.
- Microscopic: eg)cytology (cells), histology (tissues).

Physiology: Function- dynamic study.

- Molecular: eg) cellular proteins.
- Cellular: eg) cellular interaction.
- Systemic: eg) renal, cardiovascular.

Organisation of Human Body:

- Atomic->molecular level: atoms interact to form molecules.
- Molecular->cellular level: molecules combine to form organelles & therefore cells.
- Cellular->tissue level: numerous cells join together to form tissue.
- Tissue->organ level: tissues are a group pf similar cells working together t/w common function.
- Organ->system level: eg)kidneys+ureter+bladder=renal system.
- System->organism.

Characteristics of an Organism:

- Organisation: Relationships between parts of the organism & how they interact to perform specific functions.
- Metabolism: Chemical reactions in the organism.
- Responsiveness: Ability to sense changes in int/ext environment and adjust.
- Growth: increase size and number of cells.
- Development: changes over time.
- Reproduction: Formation of new cells/organisms.

Homeostasis: Existence & maintenance of a relatively constant (normal range) int environment. Set point= ideal.

- Major Disturbance: may never recover eg) stroke, excessive bleeding.
- Minor: easy to recover from eg) temp, slight dehydration.

Anatomical Position and other Positions: Use a point of reference.

- Features: standing erect, head and eyes forward facing, feet flat facing forward, arms straight by sides, forearms supinated with palms forward.
- Other Positions: supine (face up) and prone (face down).

Directional Terms:

Superior (cephalic/ cranial)	T/w head/ above	Elbow superior to wrist
Inferior (caudal)	T/w tail/lower	Right kidney inferior to liver
Anterior (ventral)	T/w front	Sternum anterior to heart
Posterior (dorsal)	T/w back	Right kidney posterior to liver
Proximal (limbs)	Closer to point of attachment	Knee proximal to ankle
Distal	Farther from point of attachment	Elbow is distal to shoulder
Medial	t/w midline	Nose medial to eye
Lateral	Away from midline	Nipple lateral from sternum
Superficial	Close to surface of	Skin is superficial to muscle
Deep	internal	Lungs deep to ribs

Body Planes:

- Saggital: vertical, left & right. Median/mid sag= even, para=uneven.
- Frontal: (coronal), vertical , anterior and posterior.
- Transverse: (horizontal) parallel to ground, superior and inferior.

Divisions of Abdomen:

- Quadrants:

RUQ	LUQ
RLQ	LLQ

- Regions:

RIGHT HYPOCHONDRIAC	EPIGASTRIC	LEFT HYPOCHONDRIAC
RIGHT LUMBAR	UMBILICAL	LEFT LUMBAR
RIGHT ILIAC	HYPOGASTRIC	LEFT ILIAC

Body Cavities:

- Thoracic: separated from abdominal cavity by diaphragm, separated into left and right by mediastinum: oesphogus, trachea, b.vessels, thymus, heart, nerves
- Abdominal: stomach, spleen, intestines, liver, kidneys, pancreas. Enclosed by abdominal muscles anteriorly.
- Pelvic: bladder, parts of large intestine, reproductive organs, Enclosed by pelvic bones

Compendium 2- Cell structure & arrangement of cells into tissues:

Cell: structural & functional unit of organisms.

- Functional Characteristics: cellular metabolism, energy use, synthesis of molecules, communication, reproduction, inheritance.
- Examples of extracellular environment:
  -Blood cell->fluid environment
  -Bone cell->hardened, calcified tissue
  -Cell lining stomach->acidic
  -Muscle cell in calf->other muscle cells, acidic
  -Cell on skin surface->dry and abrasive, tightly packed with other cells

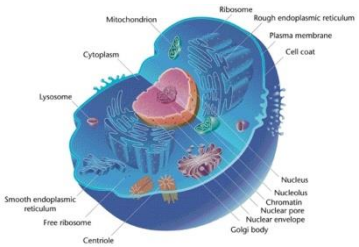

Organelles:

- Plasma Membrane: Encloses and supports cellular contents, controls what goes in/out, intercellular communication. Structure:phospholipid bilayer, cholesterol, carbs, proteins, glycocalyx=outer.
- Cytoplasm: Components outside nucleus but inside membrane. Organelles+cytosol(fluid). Cytoskeleton=structure, support, shape.
- Nucleus: Holds specific genetic material so therefore determines structure & function. Nuclear envelope=bilayer, porous. Nucleoplasm, Nucleous=ribosome production.

- Ribosomes: Protein synthesis site, free->in cytoplasm, attached to rough ER.
- Endoplasmic Reticulum: Flattened interconnecting sacs and tubules. Rough= synthesis and mod of proteins. Smooth= lipid, steroid and carb synthesis, detox, glycogen breakdown, therefore expect lots in liver, ovary and teste cells.
- Golgi Apparatus: Flattened membrane sacs with fluid filled cisternae, secretory vesicles-> mods, packages and distributes proteins and lipids from ER. Expect extensive GA in pancreatic and goblet cells of stomach (insulin and mucous are proteins).
- Lysosomes: Membrane bound vesicle formed at GA contain digestive enzymes.
- Mitochondria: Bilayer membrane, matrix, changes shape and has own DNA therefore can replicate, produces ATP, lots of liver and kidney.
- Centrioles: Barrel shaped, 2 @ right angles to eachother made of microtubules formed at centrosome-> cell division.
- Cilia: hair like, motile, cellular extensions of outer surface of certain cells, moves substances across cell surface.
- Flagella: sperm cells, moves cell.
- Microvili: extensions of cell membrane, non-motile, increase SA.