MUSCULOSKELETAL PHYSIOTHERAPY III

WEEK 1: INTRODUCTION TO MUSCULOSKELETAL PHYSIOTHERAPY

Conceptual Framework

Determine the main presenting problem:

- Problems:
  - Impairment (ROM, strength, motor control)
  - Disability
  - Participation
  - Beliefs, behaviors
  - Symptom control
- Objective measurement of main presenting problem
- Select intervention matched to main presenting problem
- Select appropriate dosage
- Set treatment goals, anticipated timeframe, number of treatments (cost)
- Implement treatment and monitor progress towards goals

Classification of Regional Pain complaints:

1. History
2. Physical examination
3. Screen red flags
4. Neurological exam
5. Assess yellow flags
6. Radiology
7. Identify cause of pain

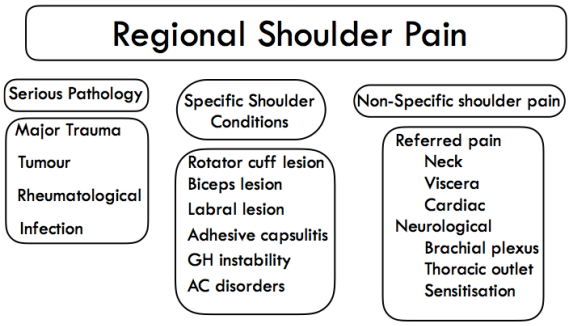

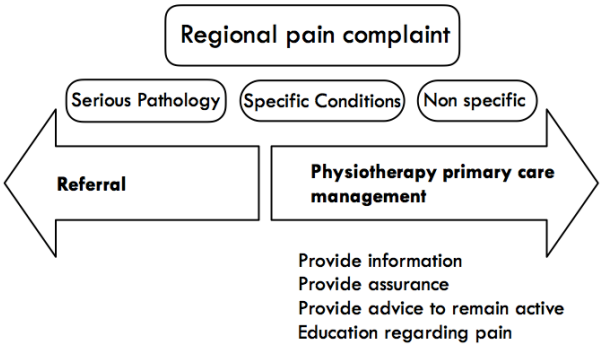

How do you determine if there is a serious pathology:

- History- get a comprehensive picture of a patients health
  - Current and previous health issues
  - Current and previous medical treatment
  - Patients health in general
  - Factors which might affect patients health and response to treatment (risk factors, lifestyle issues)
  - Their family's health
- Red flags: determine if symptoms are visceral or potentially life threatening
  - EG left shoulder pain could mean myocardial infarction, ruptured spleen
  - Right shoulder pain could be liver disease, carcinoma, stomach, pancreas, gall bladder problems, cholecystitis

- Both shoulders could be Pancoast's Tumor
- Yellow Flags:
  - Passive coping tendencies
  - Depression
  - Fear avoidance
  - Pain syndromes
  - Concurrent psychological illness

Fractures:

- May result from trauma such as falls onto outstretched arm
- Clavicle fractures:
  - Usually from direct blow to shoulder → axial compression
  - Note: clavicle acts as a strut- point of force transfer between arm and trunk that allows for large range of movement
  - Middle 1/3 most common (80%) followed by distal (10-15%) and medial (3-5%)
  - Mid shaft have low rate of mal-union → doesn't require surgery unless displaced
- Humeral fractures:
  - Surgical neck fracture= most common, particularly in elderly
  - Greater tuberosity, shaft and intercondylar fractures less common
  - Require 6-8 weeks protective phase without bone loading
- Forearm fractures:
  - Radial shaft= solitary fracture distal 1/3 radius with dislocation from the ulnar at radioulnar joint (Galeazzi fracture)
  - Ulnar shaft= solitary mid shaft
  - Moteggioas fracture= reverse radial shaft= fractures proximal 1/3 ulna with dislocation radial head
- Distal forearm fractures:
  - Colles fracture= fracture of radius in the wrist with bwds displacement of hand
  - Smith fracture= distal radius from fall onto flexed wrist (reverse Colles)
  - Ulnar styloid
  - Barton and reverse barton= intra-articular fracture of distal radius with dislocation radiocarpal joint

<u>WEEK 2:</u> ELBOW ANATOMY AND BIOMECHANICS

Distal Humerus:

- Note: Olecranon fossa is not round and commonly → impingement